



ELSEVIER

A case series of recurrent myotendinous rotator cuff tears repaired and augmented with dermal allograft: clinical outcomes at two years

Teresa Hall, DO^{a,*}, Kristopher Danielson, DO^a, Shawn Brandenburg, DO^a,
Thomas Matelic, MD^b

^a*Metro Health – University of Michigan Health Hospital, Wyoming, MI, USA*

^b*Orthopaedic Associates of Michigan, Grand Rapids, MI, USA*

Introduction: When rotator cuff tears occur after a primary repair at the footprint, they often fail medially at the myotendinous junction, also called type II tears. These are difficult tears to treat, and little research has been published on how to address tears at the myotendinous junction and the clinical outcomes of the revised repairs. The purpose of this study is to evaluate the outcomes of type II rotator cuff tears repaired with a dermal allograft augmentation.

Materials and methods: We conducted a retrospective chart review of 9 patients with a type II rotator cuff tear medially at the myotendinous junction, arthroscopically repaired and augmented with acellular dermal allograft by a single surgeon. Two-year follow-up was obtained to evaluate pain, function, range of motion, and structural integrity of the repair via ultrasound.

Results: Of all 9 patients, the mean visual analog scale preoperatively was 5.1 (standard error, ± 2.1). With 9 patients having 2-year follow-up, the mean visual analog scale score continued to improve to 1.9 (standard error, ± 2.4). At 2 years, the mean American Shoulder and Elbow Surgeons based on 8 patients was 76.1, and the mean Short Form 36 for all 9 patients was 78.7. All 9 patients with 2-year follow-up had an intact repair on ultrasound read by a musculoskeletal fellowship-trained radiologist.

Discussion: Based on the early outcome data, patient satisfaction scores, and intact repairs visualized on ultrasound at 2 years post-operatively, the use of acellular human dermal matrix augmentation appears to be an efficacious and worthwhile treatment option for patients with recurrent rotator cuff tears at the medial myotendinous junction.

Level of evidence: Level IV; Case Series; Treatment Study

© 2020 Journal of Shoulder and Elbow Surgery Board of Trustees. All rights reserved.

Keywords: Shoulder; rotator cuff; arthroscopy; acellular dermal allograft; myotendinous junction tears; revision

Musculotendinous injuries of the rotator cuff have been classified as medial tears of the cuff that occur primarily from trauma or secondarily after a previous rotator cuff

repair at the bony footprint. The latter is classified as a type II failure and has been hypothesized to occur due to knot placement with friction or impingement of the knot on

The surgeries and ultrasounds in this study were performed at Metro Health Hospital. The retrospective chart review and patient interviews were conducted at Orthopaedic Associates of Michigan.

This study was reviewed according to international, national, and institutional guidelines concerning the ethical treatment of human subjects, and complies with relevant legislation. It has been approved by the Metro Health IRB committee under full board review (2017-004), which covers the institution (OAM Metro Health Surgery Center) and the practice

(Orthopaedic Associates of Michigan, PC) where the studies were conducted. All subjects were consented per GCP and FDA/ICH guidelines, and were consented per institutional standards of practice with an IRB-approved consent form before study participation.

*Reprint requests: Teresa Hall, DO, Metro Health – University of Michigan Health Hospital, 5900 Byron Center Ave SW, Wyoming, MI 49519, USA.

E-mail address: teresa.buiocchi@gmail.com (T. Hall).

musculotendinous junction tissue, stress concentration medially, or strangulation of tissue leading to failure.¹⁵

Rupture of the myotendinous junction usually affects the infraspinatus muscle,^{14,15,19,24} but this pathology also occurs in the supraspinatus muscle.^{7,23} These injuries have been sparsely described in the literature and involve patients with previously undiagnosed rotator cuff tears. These types of tears can be diagnosed via ultrasound or magnetic resonance imaging (MRI).^{24,25}

Previous studies have shown that older age, larger tear size, and poorer muscle quality are all associated with poorer healing after rotator cuff repair.^{2,5,8,9,11,20,22,25} Tashjian et al demonstrated that increased tendon retraction, fatty infiltration, and a more medialized preoperative musculotendinous junction position are all associated with inferior healing after single-row rotator cuff repair. In their study, if the musculotendinous junction was lateral to the glenoid face before the surgical repair, there was over a 90% chance of healing, whereas if the musculotendinous junction was medial to the glenoid face, the chances of healing were approximately 50%.^{16,20,21}

New methods of tendon repair have been developed to improve outcomes in a revision rotator cuff repair setting. Precisely, rotator cuff augmentation using biologic patches has been proposed as a method to improve repair integrity, particularly when tendon quality is less than optimal. Although the most appropriate materials for the augmentation of rotator cuff repairs have not yet been defined, preliminary biomechanical and clinical evidence suggests that rotator cuff augmentation may be an effective method for the treatment of massive, retracted rotator cuff tears.^{1,3,6,13,17,21}

To our knowledge, there has been no literature published to date describing the use of dermal allograft augmentation of a type II rotator cuff tears at the myotendinous junction during revision surgery. The aim of this investigation was to analyze the outcomes of patients with type II rotator cuff tears at the myotendinous junctions after previous surgical repair, who were revised with augmentation using dermal allografts, specifically: (1) to identify the clinical and functional outcomes of these patients at various postoperative intervals for 2 years, and (2) to identify the structural integrity of the type II tear repair with dermal allograft at 2 years postoperatively via ultrasound, and correlate clinically. The hypothesis of the authors is that patients in a small case series of a single surgeon's method would have improved pain and function, would return to work or presurgical activity level, and would have an intact allograft augmentation of the rotator cuff visualized at 2 years postoperatively on ultrasound.

Materials and methods

Institutional review board approval was obtained before the initiation of this retrospective case series study. Between January

2012 and December 2015, a retrospective case series review was performed. Nine patients with full thickness myotendinous tears who previously underwent rotator cuff repair were revised with the use of acellular dermal allograft by a single surgeon. Patients over age 18, with a minimum of 2 years of follow-up, and who underwent previous rotator cuff repair at the bony footprint were included and underwent an open, primary repair of musculotendinous rotator cuff tear augmented with dermal allograft. Patients who were pregnant, who already underwent revision surgery with dermal allograft augmentation, who sustained additional shoulder trauma after index procedure, who had insufficient follow-up, and who had malignancy and/or were felt to have confounding diagnosis at the discretion of the investigator were excluded. Treatment failure was declared when subsequent revision cuff repair or reverse total shoulder arthroplasty was performed after the initial revision with dermal allograft. Patients with a minimum of 2 years of follow-up were then consented appropriately for clinical follow-up and study participation. Information collected for analysis included demographic data (age, sex, body mass index), surgical history (ie, previous rotator cuff repairs), patient satisfaction questionnaire, activity level, return to work or sport, standard shoulder examination, and postoperative x-rays compared with contralateral. At least 2-year follow-up ultrasounds were performed and interpreted by a board-certified musculoskeletal radiologist to evaluate the integrity of the revised rotator cuff with dermal allograft. Clinical outcome scores were collected pre- and postoperatively and included Short Form 36, American Shoulder and Elbow Surgeons (ASES), Constant Shoulder score, and visual analog scale (VAS) pain scores. These same patients were assessed by the senior surgeon and postgraduate year 3 or 4 orthopedic surgery resident during follow-up visits. Functional failures were defined as patients with satisfaction scores of 6 or less.

Surgical technique

Patients with suspected type II tears of the rotator cuff after previous rotator cuff repair, which occur primarily medial to the footprint at the myotendinous junction on MRI, were consented for arthroscopy and then arthroscopy vs. open rotator cuff repair with potential dermal allograft augmentation. All patients included in this study were found to have tears of the supraspinatus and partial tears of the infraspinatus at the myotendinous junction and were treated with diagnostic arthroscopy and then mini open rotator cuff repair with the deltoid-splitting approach. First, a repair was performed using traditional anchors on the most medial aspect of the bony footprint when possible and/or a side-to-side conversion sutures depending on the shape of the tear. Because of the location of these tears, the tissue quality was felt to be poor with too much tension on the repair, and a traditional dermal allograft patch was used to augment the repair. A bridging technique was not used for any of the patients in this case series. The graft was sized to cover the rotator cuff tear and deficient tissue with 1 cm of graft overlap in all directions. It was then incorporated in the stiches of the rotator cuff repair medially and then laterally to create a patch-like construct over the top of the graft and sewn in laterally with suture to the periosteum or with anchors, as demonstrated in Fig. 1. A schematic illustration of the construct configuration is demonstrated in Fig. 2. The epidermal side of the graft was placed so it was visualized superiorly and the

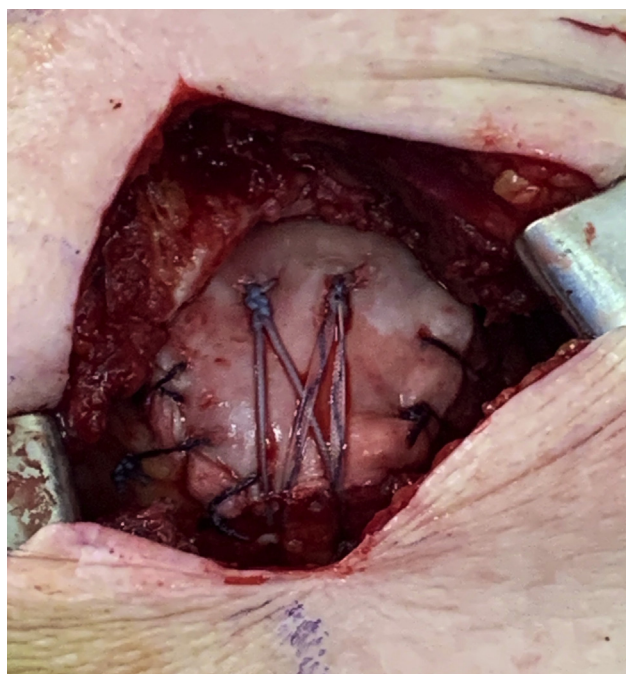


Figure 1 An intraoperative photograph demonstrating a bird's-eye view of the completed repair and augmentation. Medial row suture anchors are placed at the medial aspect of the rotator cuff footprint, through the medial side of the musculotendinous junction tear and acellular dermal allograft. These sutures are secured with a lateral row of anchors, in a crisscross pattern for compression of the graft to the myotendinous junction tear. Finally, a circumferential baseball stitch was performed to aid in securing the graft to the tendon and musculotendinous junction below.

graft repair and augmentation were reinforced with a running baseball suture circumferentially. A traditional closure was performed. Postoperatively patients were kept in an abduction sling for 4 weeks and allowed to do active pendulum exercises 3 times daily. Then they were progressed to formal physical therapy. Initially passive exercises were begun. Range of motion excesses were allowed, followed by light resistance exercises at 6 weeks, and strengthening exercises were advanced slowly as tolerated. At 4-6 months, they were allowed to return to all activities without restriction.

Results

Patients included those over age 18 with previous rotator cuff tear at the footprint who underwent initial direct surgical repair and sustained a second tear postoperatively occurring at the myotendinous junction. These were then fixed by the same surgeon and augmented with dermal allograft. In total, 9 patients were identified in the study. There were 5 females and 4 males between the ages 43 and 63 (mean, 55), see [Table I](#). Body mass index ranged from 23.6 to 36.0 (mean, 28.5). One patient was a current

smoker, and 2 patients were former smokers. See [Table I](#) for demographics.

The mean VAS preoperatively was 5.1 (standard error [SE], ± 2.1), with a median of 6/10 before revision surgery. At 2-month follow-up, the mean VAS score improved to 2.1 (SE, ± 2.1), with a median of 2/10. All 9 patients had a minimum of 2-year follow-up. At 2 years postoperatively, the mean VAS score continued to improve to 1.9 (SE, ± 2.3), with a median of 1/10. At the 2-year follow-up, Qualitative Constant Shoulder scores ranged from good to excellent postoperatively. The mean ASES was 76.1 based on 8 patients. The mean Short Form 36 score was 78.7. The mean Quantitative Constant Shoulder score was 8 (range, -9 to 19), all with good to excellent Qualitative Constant Shoulder scores at 2 years postoperatively. See [Table II](#) for a list of pre- and postoperative pain and functional scores by patient. Three patients reported recalling difficulty returning to work, school, or previous level of activity. No patients remained on pain medications at 2 years. No patient had an effusion, erythema, edema, or wound healing problems, and all remained neurovascularly intact.

Range of motion at 2 years postoperatively was well within functional ranges. The mean active forward flexion was 176° (range, 160° - 180°). The mean active abduction was 173° (range, 145° - 180°). The active cross-arm adduction was 45° for all 9 patients. The mean active external rotation with the arm adducted to the side was 48° (range, 15° - 65°). The mean active external rotation with the shoulder in 90° of abduction was 84° (range, 60° - 90°). The mean active internal rotation in 90° of abduction was 67° (range, 30° - 90°). Postoperatively, all 9 patients had a negative empty can, belly press, and lift-off test. Of 9 patients, 8 had 5/5 infraspinatus strength postoperatively and 1 had 3/5 infraspinatus strength. The median supraspinatus strength testing was +4/5 and the mode was 5/5 (range, 3/5-5/5). See [Table III](#) for pre- and postoperative strength and postoperative range of motion.

One of 9 patients sustained complications. The patient experienced transient swelling about the elbow and ulnar nerve paresthesias associated with sleep and work. This resolved with conservative management and did not prevent the patient from returning to work. The patient did not require ulnar nerve decompression or transposition.

Nine patients had 2-year clinic follow-up for pain, function, and range of motion. In addition, they underwent an ultrasound to evaluate integrity of the revision rotator cuff repair with dermal allograft. All ultrasounds were performed by a single radiologist who is fellowship trained in musculoskeletal radiology. All 9 patients were found to have an intact rotator cuff repair after dermal allograft augmentation at 2 years postoperatively. Preoperative MRI and postoperative ultrasounds of 1 patient are shown in [Fig. 3](#), A-C, respectively. None of the patients required a reverse total shoulder or tendon transfer for persistent pain or lack of function. With 4 years of follow-up on 1 patient, she did sustain a subsequent rotator cuff tear after dermal

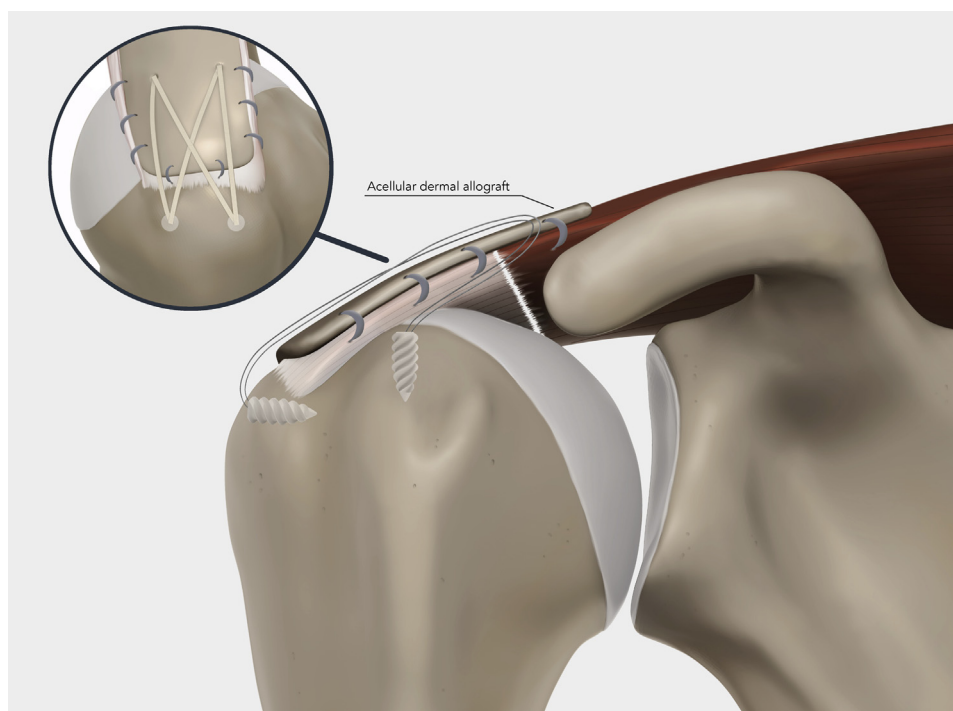


Figure 2 A medical illustration demonstrating the surgeon's construct using a coronal cross-section view. Medial row suture anchors are placed at the medial aspect of the rotator cuff footprint, through the medial side of the musculotendinous junction tear and acellular dermal allograft. These sutures are secured with a lateral row of anchors, in a crisscross pattern for compression of the graft to the myotendinous junction tear. Finally, a circumferential baseball stitch was performed to aid in securing the graft to the tendon and musculotendinous junction below.

Table I Patient demographics

	Age	Sex	BMI	Occupation	Smoker	Tear on MRI
1	59	F	36.0	House keeper	Never	Supraspinatus
2	50	F	25.8	Legal assistant	Never	Supraspinatus
3	46	F	25.7	Custodian	Current	Supraspinatus
4	59	M	33.0	Maintenance	Never	Supraspinatus
5	52	F	24.1	Broadcasting	Never	Supraspinatus, Infraspinatus
6	43	M	26.1	Farmer	Never	Supraspinatus
7	63	M	32.3	IT	Former	Supraspinatus
8	63	M	23.6	House keeper	Former	Supraspinatus
9	60	F	29.5	Factory worker	Never	Supraspinatus, Infraspinatus

BMI, body mass index; *MRI*, magnetic resonance imaging.

allograft augmentation. This was sustained in a traumatic nature and occurred at the bony footprint, not at the myotendinous junction repair. She underwent a third rotator cuff repair and clinically has been doing well with the limited follow-up.

Discussion

Literature regarding rotator cuff tears at the myotendinous junction is sparse. Usually, the infraspinatus is involved, but the supraspinatus can be affected as well.^{7,23} This specific

type of tear may not be well described due to these patients going undiagnosed. Tears at the myotendinous junction often occur in older patients with large rotator cuff tears with poor muscle quality or fatty infiltration who subsequently undergo an arthroscopic rotator cuff repair.^{2,5,8,9,11,20,22,25} A previously proposed technique for revision rotator cuff repair uses dermal allograft as an augment for tendon repair. Preliminary biomechanical studies have shown this to be a potential option that is successful with good clinical outcomes in a particular problem that is technically difficult to treat. Clinical studies have shown dermal allograft or a biologic patch to be effective in improving pain and function in revision rotator

Table II Pre- and postoperative VAS and functional scores

	Pre-VAS	2-month VAS	2-year VAS	2-year ASES	2-year SF-36	2-year Quantitative Constant Shoulder	2-year Qualitative Constant Shoulder
1	6	0	6	60	77	3	Excellent
2	6	0	1	57	83	3	Excellent
3	5	3	6	X	29	12	Good
4	6	5	1	87	61	12	Good
5	8	1	2	87	89	14	Good
6	1	2	1	95	93	-9	Excellent
7	5	0	0	92	94	19	Good
8	2	2	0	97	93	13	Good
9	7	6	0	95	89	5	Excellent

VAS, visual analog scale; ASES, American Shoulder and Elbow Surgeons; SF-36, Short Form 36.

Table III Pre- and postoperative strength and postoperative range of motion

	Pre-supraspinatus strength	2-year supraspinatus strength	2-year forward flexion	2-year abduction	2-year cross-arm adduction	2-year external rotation (at side)	2-year external rotation (90° abduction)	2-year internal rotation (90° abduction)
1	-4	-4	180	180	45	65	90	65
2	3	+4	180	180	45	65	90	50
3	3	-5	160	160	45	15	90	30
4	3	5	160	145	45	35	75	90
5	3	3	180	180	45	35	60	70
6	3	5	180	180	45	65	90	90
7	3	-4	180	180	45	30	90	30
8	3	+4	180	180	45	65	90	90
9	4	5	180	170	45	60	70	90

cuff repairs. To our knowledge, this is the first study to evaluate the use of dermal allograft in revision rotator cuff repairs for type II tears, as described by Zarin and Ciullo, at the myotendinous junction, and also investigates the integrity of the repair postoperatively, correlating patient pain and function.^{1,13,17,21}

Nine were reachable and agreed to be evaluated. All patients at that time were at least 2 years from their revision rotator cuff repair. All 9 patients (100%) who were available underwent ultrasound evaluation by a fellowship-trained musculoskeletal radiologist to assess integrity of the rotator cuff repair with dermal allograft. One hundred percent of those patients' cuffs augmented with allograft remained intact at the 2-year mark or beyond. The patients were also evaluated with pain and functional scores. The results of these patient-reported outcomes were very encouraging. Not only was the dermal allograft augment visualized intact in type II rotator cuff tears using ultrasound, but they also profoundly improved function and provided pain relief immediately postoperatively and 2 years postoperatively.

A systematic literature review of primary rotator cuff repairs indicated a failure rate of approximately 20%.¹²

Functional outcome is correlated with postoperative cuff integrity and is attributed to the preservation or loss of force coupling. Ladermann et al¹² performed a systematic review of failed rotator cuff repairs and demonstrated factors such as poor tendon quality, poor muscle quality, and poor greater tuberosity bone quality as being associated with failures. In evaluating suspected rotator cuff failures, ultrasound is becoming a popular modality for a number of reasons. Ultrasound is affordable and permits a dynamic evaluation, whereas MRI images can be difficult to interpret after a repair. Postsurgical repair MRI may show intermediate signal within the repaired tendon caused by granulation tissue that can persist for longer than 6 months. This signal can be attributed to remodeling of the healing tendon, a normal leakage of fluid into the subacromial space where arthroscopic instruments were previously passed, and artifact caused by metal anchors or high-strength sutures. In the study by Ladermann, a combined evaluation of revision rotator cuff repairs performed arthroscopically and open had a patient satisfactory score of 70%, with a re-revision rate of 10%. The most important factor in clinical outcome was preoperative range of motion. Because of the quality and nature of the study, no

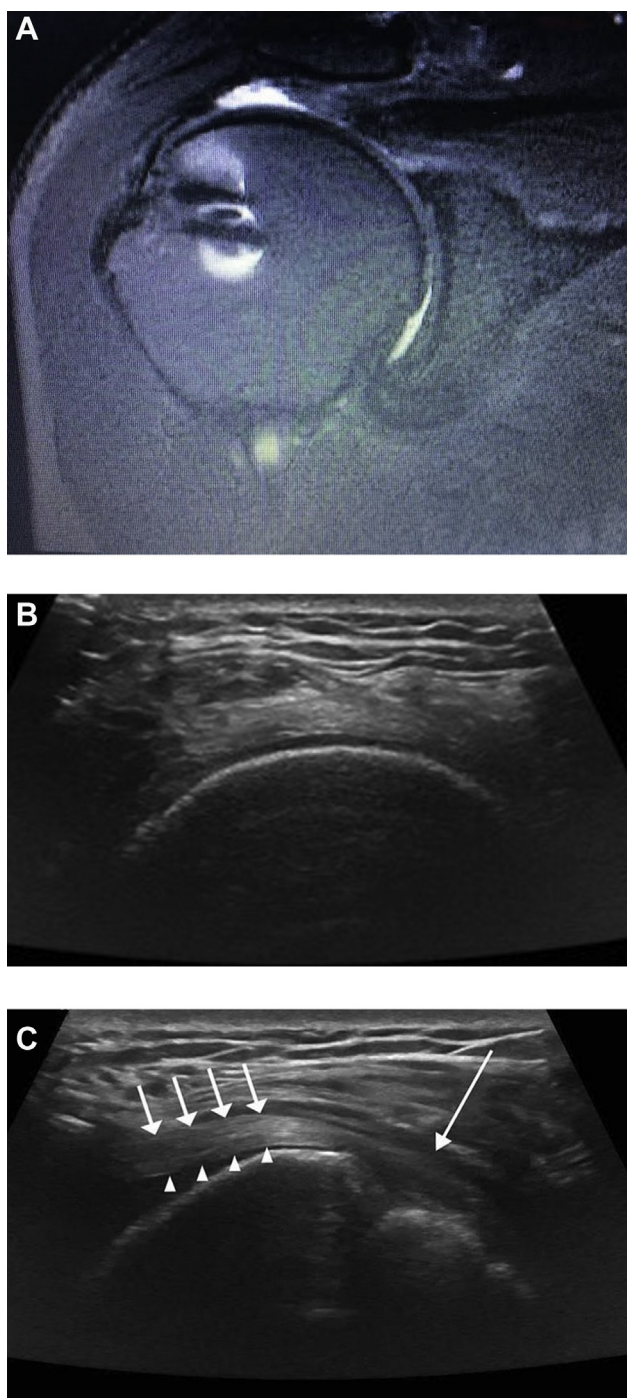


Figure 3 (A) A preoperative coronal T2 image showing hyperintense signal at the myotendinous junction of the supraspinatus muscle, indicative of a complete tear with the intact tendon remaining laterally attached to the tuberosity at the footprint. (B) Short-axis sonographic image of the supraspinatus tendon that demonstrates the supraspinatus tendon intact inferiorly and the respectively superficial dermal allograft is also intact. (C) Long-axis sonographic image of the supraspinatus tendon of the same patient postoperatively after dermal allograft augmentation. —: rotator cuff footprint with the intact tendon attached to the footprint. →: supraspinatus tendon allograft. ▲ native supraspinatus tendon fibers inferior to the graft.

definitive recommendations could be advised for treatment options of failed rotator cuff repairs. The options include arthroscopic revision, augmented repairs, tendon transfers, and reverse total shoulder arthroplasty, all of which are determined by patient-specific factors. Unfortunately, few studies of myotendinous junction repairs have been described in the literature and therefore were not specifically addressed in this systematic review.¹²

In 2016, Millett et al¹⁵ redescribed Zarins and Ciullo's 1983 original classification of rotator cuff tears at the myotendinous junctions. Millett redescribes primary tears at the musculotendinous junction as type I tears, which are much less common than tears off the bone at the footprint. The treatment of this type of tear involves a complex bridging suture repair, with a medial and lateral row of anchors, and sometimes debriding 1-2 mm of articular surface on the humeral head is required. Type II would describe those reviewed in this paper: chronic medial cuff tears, with poor quality or too short of a medial tendon however healthy muscle. These types of tears usually occur as retears after a primary cuff repair at the cuff footprint. It is speculated that these tears occur because the arthroscopic knot placement causes abrasion or subacromial knot impingement with medial stress concentration, resulting in tendon strangulation and failure. The treatment of these tears is recommended with a bridging repair with graft augmentation. Augmentation aids in the strength and integrity of the short or absent medial aspect of the tendon, to assist with knot security. This can also be used to bridge a tissue defect if there is insufficient excursion laterally of the medial cuff, although the Food and Drug Administration has only approved this device for use in bridging less than a 1-cm gap. Allografts have been shown to have better outcome than xenografts. This technique can be performed arthroscopically or open. Lastly, Millett describes a type III tear as a medial tear with the retracted medial tendon and atrophied muscle with fatty infiltration. Treatment for this is an interposition graft such as a superior capsule reconstruction, a latissimus dorsi tendon transfer, or reverse total shoulder arthroplasty.¹⁵

Petri et al¹⁸ published their outcomes of open repair of revision rotator cuff tears medially at the myotendinous junction, using a biologic patch for augmentation, not bridging. They primarily evaluated clinical outcomes at 2 years. Their study included 13 shoulders with 1 previous rotator cuff repair. None of their patients required further surgery, and over a mean period of 2.5 years of follow-up, the ASES score improved by more than 20 points. In their results, they did not have a significant improvement in the pain component of the ASES score; however, functionally they improved from their baseline preoperatively. Their results would suggest this to be an effective treatment based on clinical outcomes and are also consistent with the clinical findings of the outcomes of our study.¹⁸

While collecting and analyzing data in this study and preparing this manuscript, an article was published by

Hohn et al¹⁰ out of South California Orthopedic Institute with a similar aim to evaluate the use of an acellular human dermal matrix allograft as an augmentation for previous failed arthroscopic rotator cuff repair. Their study included a total of 28 patients, all of whom had undergone a previous repair that subsequently failed. Unfortunately, the location or type of retear was not classified in this paper, so it is unclear if these were tears augmented for retears from the bony footprint or augmented at the myotendinous junction, as was the case in our study. Over a 2-year follow-up period, 13 of 28 underwent postoperative imaging with MRI and 4 of the 13 had sustained a retear of the revision cuff repair. Their study included just 6 patients who had both preoperative and postoperative outcome scores, which demonstrated an improvement in the ASES score from 56 to 85 and the Single Assessment Numeric Evaluation score from 42 to 76, respectively. This is the only other study, to our knowledge, demonstrating patch augmentation for retears at the myotendinous junction after a previously arthroscopically repaired rotator cuff off the bony footprint, also correlating postoperative imaging with outcomes. This study highlights similar findings to our own, which indicates a need for further research on patch augmentation in this specific scenario, preferably with larger studies.¹⁰

As early studies on the topic of retears at the myotendinous junction of the rotator cuff muscles surface, they tend to be small cohort studies that lend themselves to the ground work of larger and more powerful studies. As in our study and the study by Hohn et al in 2017, the studies included surgical repairs by a single surgeon. As the ground work is laid to evaluate the efficacy of the patch augmentation on pain and function, as well as integrity of the graft with longer follow-up, it is important to investigate various types of inclusion of the patch graft or repair of the medial cuff tear. An article by Buess et al,⁴ published also in 2017, describes their technique, which is similar to the lead surgeon's technique for using a bio-absorbable patch to augment a medial rotator cuff tear after failed arthroscopic primary repair. Their technique reportedly adds a mere 30 minutes to the procedure and does not require additional use of bone anchors, making it more cost effective.⁴ Although they have no published literature on outcomes of their surgical technique, it offers orthopedic surgeons an alternative to the technique described in this paper, to add to their armamentarium depending on the type and character of tear, and it lends itself to further encouragement of research on outcomes of type II rotator cuff tears at the myotendinous junction with revision repairs.

To our knowledge, there has been only 1 other small case series published by Hohn et al that describes the use of dermal allograft augmentation for myotendinous junction rotator cuff tears for revision surgery for rotator cuff tears. The study by Petri et al¹⁸ is only the second small case series to use a dermal allograft in a similar manner, demonstrating that patch augmentation for open revisions of massive rotator cuff tears off the bone interface is promising and may provide good scaffolding for healing in this environment.

The limitations of this study include the small study size of 9 patients with follow-up of 2 years. In addition, the design of this study was retrospective. Despite the limitations, the authors believe that it will lay the foundation ultimately for a larger, multicenter prospective randomized study to evaluate clinical outcomes.

Conclusion

Based on the early outcome data and patient satisfaction scores, the use of acellular human dermal matrix augmentation appears to be an efficacious and therefore a worthwhile treatment option for patients with recurrent rotator cuff tears at the medial myotendinous junction, which can be a very technically difficult problem to treat. This study revealed improved pain, function, and imaging with ultrasound demonstrated integrity of the biologic patch augmentation at a minimum of 2-year follow-up.

Acknowledgments

The authors thank Lindsey Behrend and Michelle Padley for all their support of this research in IRB approval, research design, and coordinating patient follow-up. They also thank Dr. Lisa Walker, MD, for her efforts in participating in this study by performing and reading the ultrasounds.

Disclaimer

The other authors, their immediate families, and any research foundations with which they are affiliated have not received any financial payments or other benefits from any commercial entity related to the subject of this article.

References

1. Baker AR, McCarron JA, Tan CD, Iannotti JP, Derwin KA. Does augmentation with a reinforced fascia patch improve rotator cuff repair outcomes? *Clin Orthop Relat Res* 2012;470:2513-21. <https://doi.org/10.1007/s11999-012-2348-x>
2. Boileau P, Brassart N, Watkinson DJ, Carles M, Hatzidakis AM, Krishnan SG. Arthroscopic repair of full thickness tears of the supraspinatus: does the tendon really heal? *J Bone Joint Surg Am* 2005;87:1229-40. <https://doi.org/10.2106/jbjs.d.02035>
3. Bond JL, Dopirak RM, Higgins J, Burns J, Snyder SJ. Arthroscopic replacement of massive, irreparable rotator cuff tears using a GraftJacket allograft: technique and preliminary results. *Arthroscopy* 2008;24:403-9. <https://doi.org/10.1016/j.arthro.2007.07.033>
4. Buess E, Hackl M, Buxbaumer P. Arthroscopic revision of medial rotator cuff failure augmented with a bioabsorbable patch. *Arthrosc Tech* 2017;6:e1069-74. <https://doi.org/10.1016/j.eats.2017.03.009>
5. Cho S, Lee BG, Rhee YG. Arthroscopic rotator cuff repair using a suture bridge technique: is repair integrity actually maintained?

- Am J Sports Med 2011;39:2108-16. <https://doi.org/10.1177/0363546510397171>
6. Encalada-Diaz I, Cole BJ, Macgillivray JD, Ruiz-Suarez M, Kercher JS, Friel NA, et al. Rotator cuff repair augmentations using a novel polycarbonate polyurethane patch: preliminary results at 12 months' follow-up. *J Shoulder Elbow Surg* 2011;20:788-94. <https://doi.org/10.1016/j.jse.2010.08.013>
 7. Guerini H, Pluot E, Pessis E, Thevenin F, Campagna R, Feydy A, et al. Tears at the myotendinous junction of the infraspinatus: ultrasound findings. *Diagn Interv Imaging* 2015;96:349-56. <https://doi.org/10.1016/j.diii.2014.11.009>
 8. Harryman DT, Mack LA, Wang KY, Jackins SE, Richardson ML, Matsen FA 3rd. Repairs of the rotator cuff. Correlation of functional results with integrity of the cuff. *J Bone Joint Surg Am* 1991;73:982-9.
 9. Hertel R, Lambert SM. Supraspinatus rupture at the musculotendinous junction. *J Shoulder Elbow Surg* 1998;7:432-5.
 10. Hohn EA, Gillette BP, Burns JP. Outcomes of arthroscopic revision rotator cuff repair with acellular human dermal matrix allograft augmentation. *J Shoulder Elbow Surg* 2018;27:816-23. <https://doi.org/10.1016/j.jse.2017.09.026>
 11. Ladermann A, Christophe FK, Denard PJ, Walch G. Supraspinatus rupture at the musculotendinous junction: an uncommonly recognized phenomenon. *J Shoulder Elbow Surg* 2012;21:72-6. <https://doi.org/10.1016/j.jse.2011.01.038>
 12. Ladermann A, Denard PH, Burkhart SS. Management of failed rotator cuff repair: a systematic review. *J ISAKOS* 2016;1:32-7. <https://doi.org/10.1136/jisakos-2015-000027>
 13. Liem D, Lichtenberg S, Magosch P, Habermeyer P. Magnetic resonance imaging of arthroscopic supraspinatus tendon repair. *J Bone Joint Surg Am* 2007;89:1770-6. <https://doi.org/10.2106/jbjs.f.00749>
 14. Lunn JV, Castellanos-Rosas J, Tavernier T, Barthélémy R, Walch G. A novel lesion of the infraspinatus characterized by musculotendinous disruption, edema, and late fatty infiltration. *J Shoulder Elbow Surg* 2008;17:546-53. <https://doi.org/10.1016/j.jse.2007.11.016>
 15. Millett PJ, Hussain ZB, Fritz EM, Warth RJ, Katthagen JC, Pogorzelski J. Rotator cuff tears at the musculotendinous junction: classification and surgical options for repair and reconstruction. *Arthrosc Tech* 2017;6:e1075-85. <https://doi.org/10.1016/j.eats.2017.03.023>
 16. Nho SJ, Brown BS, Lyman S, Adler RS, Altchek DW, MacGillivray JD. Prospective analysis of arthroscopic rotator cuff repair: prognostic factors affecting clinical and ultrasound outcome. *J Shoulder Elbow Surg* 2009;18:13-20. <https://doi.org/10.1016/j.jse.2008.05.045>
 17. Oh JH, Kim SH, Ji HM, Jo KH, Bin SW, Gong JS. Prognostic factors affecting anatomic outcome of rotator cuff repair and correlation with functional outcome. *Arthroscopy* 2009;25:30-9. <https://doi.org/10.1016/j.arthro.2008.08.010>
 18. Petri M, Warth RJ, Horan MP, Greenspoon JA, Millett PJ. Outcomes after open revision repair of massive rotator cuff tears with biologic patch augmentation. *Arthroscopy* 2016;32:1752-60. <https://doi.org/10.1016/j.arthro.2016.01.037>
 19. Sher JS, Uribe JW, Posada A, Murphy BJ, Zlatkin MB. Abnormal findings on magnetic resonance images of asymptomatic shoulders. *J Bone Joint Surg Am* 1995;77-A:10-5.
 20. Tashjian RZ, Hollins AM, Kim HM, Teefey SA, Middleton WD, Steger-May K, et al. Factors affecting healing rates after arthroscopic double-row rotator cuff repair. *Am J Sports Med* 2010;38:2443-52. <https://doi.org/10.1177/0363546510382835>
 21. Tashjian RZ, Hung M, Burks RT, Greis PE. Influence of preoperative musculotendinous junction position on rotator cuff healing using single-row technique. *Arthroscopy* 2013;29:1748-54. <https://doi.org/10.1016/j.arthro.2016.12.010>
 22. Taneja AK, Kattapuram SV, Chang CY, Simeone FJ, Bredella MA, Torriani M. MRI findings of rotator cuff myotendinous junction injury. *AJR Am J Roentgenol* 2014;203:406-11. <https://doi.org/10.2214/AJR.13.11474>
 23. Tavernier T, Walch G, Barthelemy R, Nove-Josserand L, Liotard JP. Isolated lesion of the infraspinatus at the myotendinous junction: a new lesion. *J Radiol* 2006;87:1875-82. <https://doi.org/10.1016/j.clinimag.2007.04.021>
 24. Tempelhof S, Rupp S, Seil R. Age-related prevalence of rotator cuff tears in asymptomatic shoulders. *J Shoulder Elbow Surg* 1999;8:296-9.
 25. Walch G, Nove-Josserand L, Liotard JP, Noel E. Musculotendinous infraspinatus ruptures: an overview. *Orthop Traumatol Surg Res* 2009;95:463-70. <https://doi.org/10.1016/j.otsr.2009.06.00>